

Precision of A Metal Implant Abutment and Esthetics of An All-Ceramic Crown

Luke S. Kahng, CDT

LSK 121 division of Capital Dental Technology Laboratory, Inc.

Case courtesy of

Douglas Palmer, DDS
Oswego, Illinois

The placement of implants as a precision technique creates strength and functional location. At the same time, the esthetics provided by all ceramic restoration is unsurpassed. When the two techniques are combined we can create efficient high-quality restorations. It is exciting to see the advancements in dentistry today. Implants are an option to treat the patient without having to remove healthy tooth structure to provide support for a fixed partial denture. The benefits to these advancements are to the patient. The patient will request the best possible care or restoration, but the dentist will look at the best possible result to restore with the most conservative application satisfying the patient's esthetic and function. This has seen a growth of dental implants. The extreme makeovers, that the patient see on television and other media outlets has increased the patient's education on esthetic restorations that are being fabricated.

Doing a single tooth implant means we no longer have to be aggressive and prepare two good teeth to replace one that is missing. This adds to the challenge of selecting a material for the understructure. The understructure needs to block out the dark metal implant and still having the highest in esthetics.

There is a wide selection of material for the crown's understructure but it can be confusing. Some may not meet esthetic expectations because they are too high in opacity. Yet too much translucency does not block out the discoloration of the preparation. Translucency can allow the metal to shine through giving the look as if the patient has a dead tooth. However, it doesn't have to be that way. Just because the understructure is dark, an all-ceramic restoration can be used. The new materials and the dental technician can avoid the dead tooth look.

Case Presentation

The male patient in his late forties has been unhappy with the esthetics of his restored tooth. In Feb 1990 a root canal had been completed on tooth No. 10. The tooth had been restored with a post and core and crown.

In 2005, the patient presented the crown and post came out of the tooth. Upon examination, a fracture in the root was found. The patient was referred to a periodontist specialist for extraction of #10. After evaluation and consultation, an implant was placed immediately with a Strauman Tapered Effect SCA 12 mm., 4.1mm RN. The tooth was temporized with a transitional removable denture for esthetics.

The patient required a restoration that would look natural in the mouth despite the metal implant. The Implant is a Strauman implant (FIG 1) and a cast metal custom abutment was fabricated. The metal abutment was milled and the technique used for preparation of the abutment was 1.2 to 1.5 mm in depth around the entire abutment and margins were subgingivally 1.0 to 1.5 mm.

A restoration was needed to mask the underlying metal abutment and Procera Zirconium was selected. The Procera Zirconium is superior in strength and esthetics. Procera system is based on the use of CAD/CAM and technology for the production of porcelain crowns, fixed bridges, and Implant abutments. The fit is excellent and the coping can be successful in masking or concealing discolored teeth, metal post and cores, and metal implant abutments.

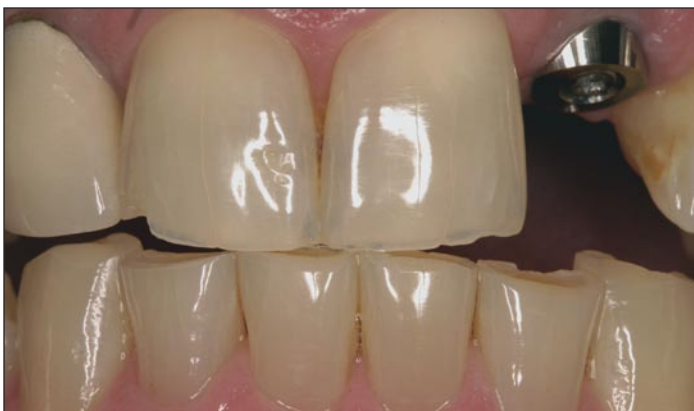

Fig. 1

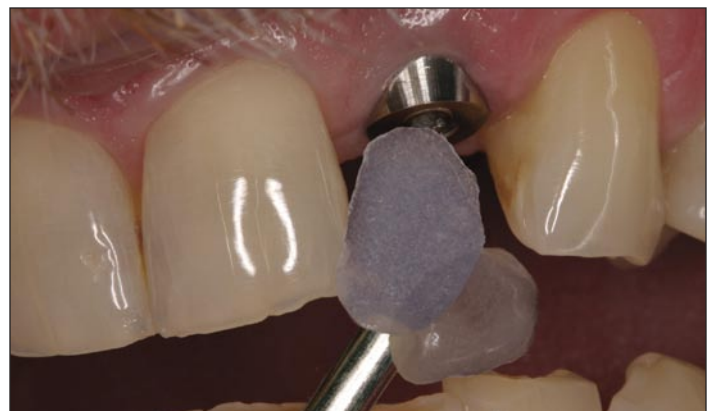

Fig. 2

Porcelain Build Up Technique

The porcelain selected was GC Initial ZR which is made specially to build on zirconium copings. The shade mapping was completed using custom made shade samples (Fig 2) and with the GC Initial shade tabs (Fig 3). The custom made shade samples are very helpful because the thickness of many shade tabs are too thick and can be too strong in value. The sample tabs can also be placed on top of each other to show you the effects you are looking for. After the shade mapping (Fig 4) is completed, a full contour wax up is completed (FIG 5). This allows you to check the room available for the restoration, if you need more room you will be able to adjust the metal abutment. You need to make sure the abutment (Fig 6) has no deep cavity and no groves are on the abutment. The full contour wax up also lets you make a putty matrix. After you are happy with the abutment, you would scan the abutment for the Procera Zirconium coping. The Zirconium coping is white and may need some internal shade modification (Fig 7). GC Initial has internal stains that can be used. The porcelain build starts with Inside porcelain powder and the Dentin shade (Fig 8) which will give you your chroma and/or opacity. The Zirconium coping and Inside and Dentin porcelain powders will give you the base to start with to block out the metal abutment. Then you can apply the effect powders and colors to fabricate the restoration.

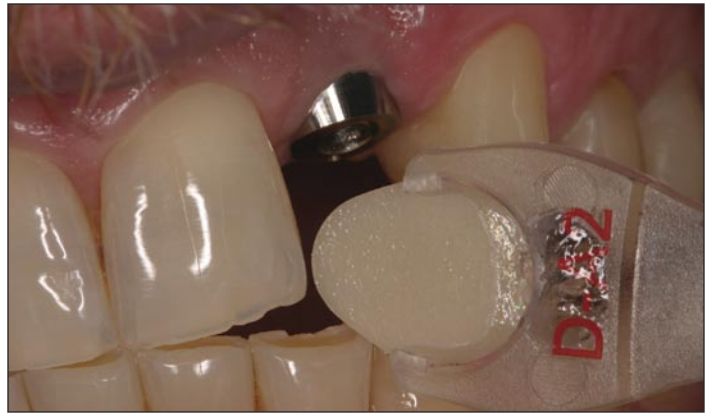

Fig.3

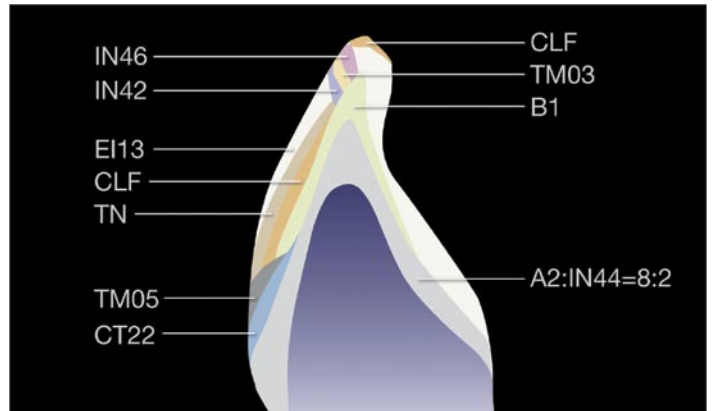


Fig.4

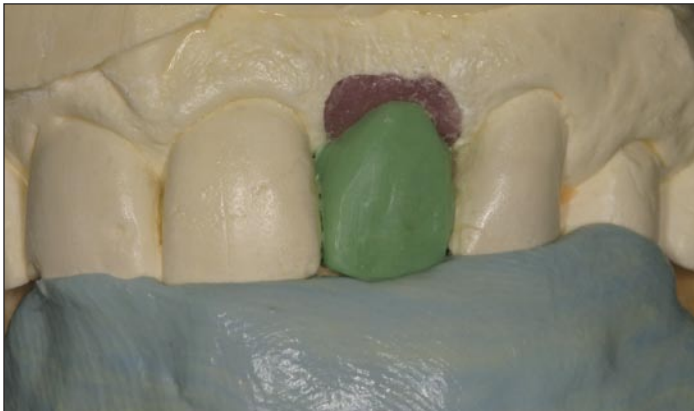

Fig.5

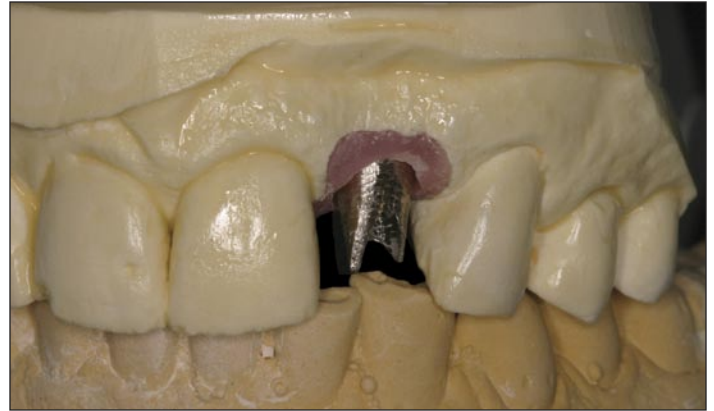


Fig.6

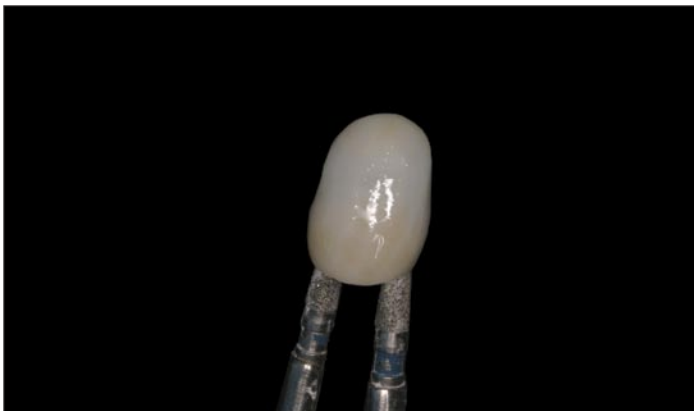


Fig.7

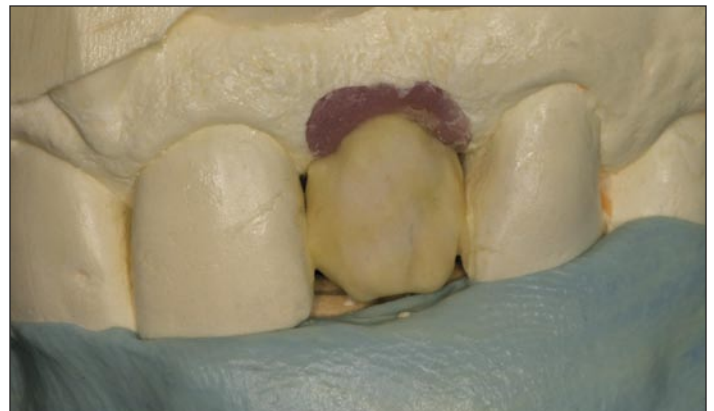

Fig.8

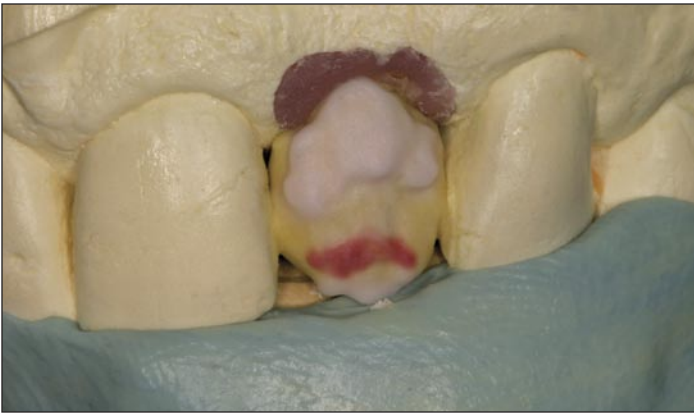

Fig. 9

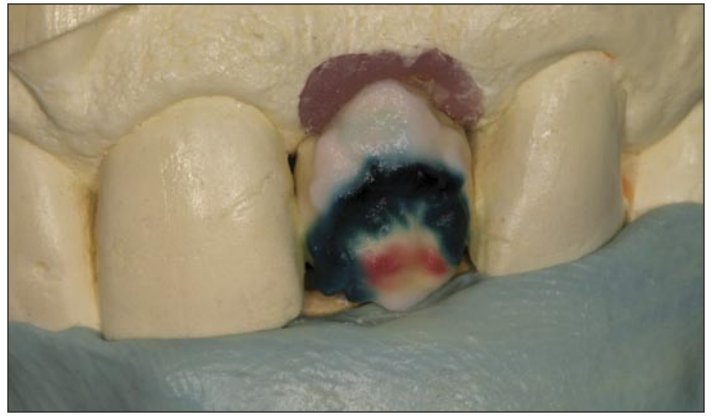

Fig. 10

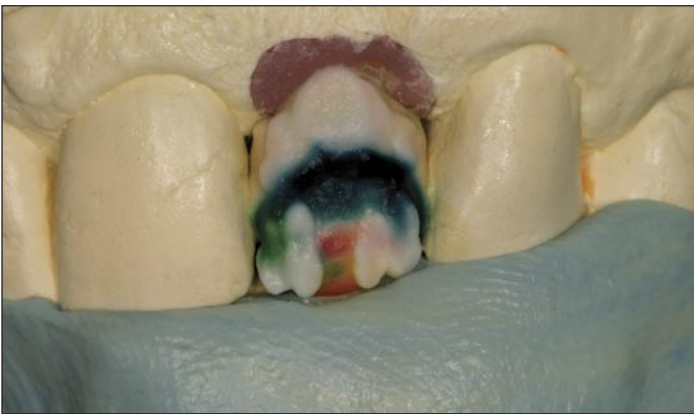

Fig. 11

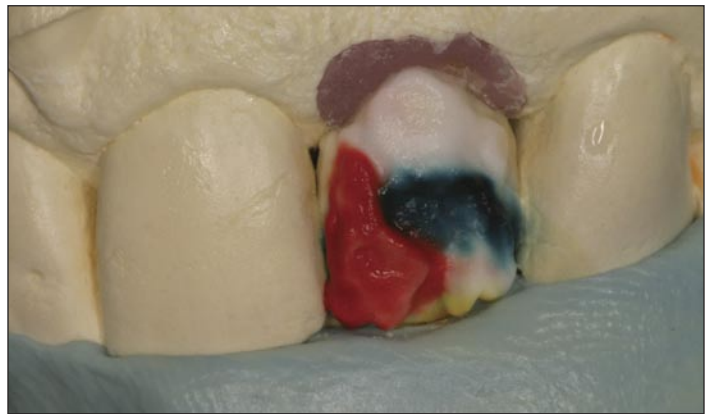

Fig. 12

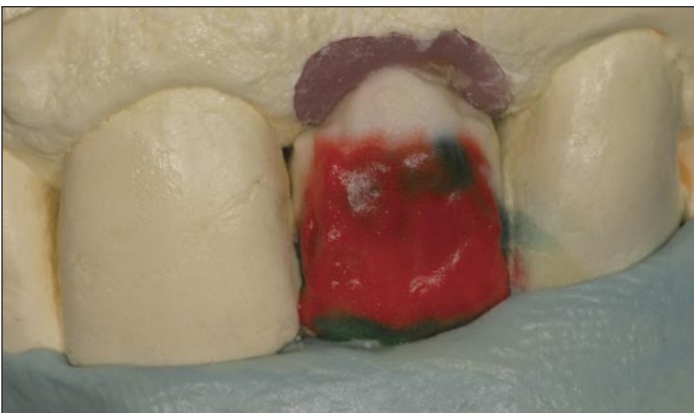

Fig. 13

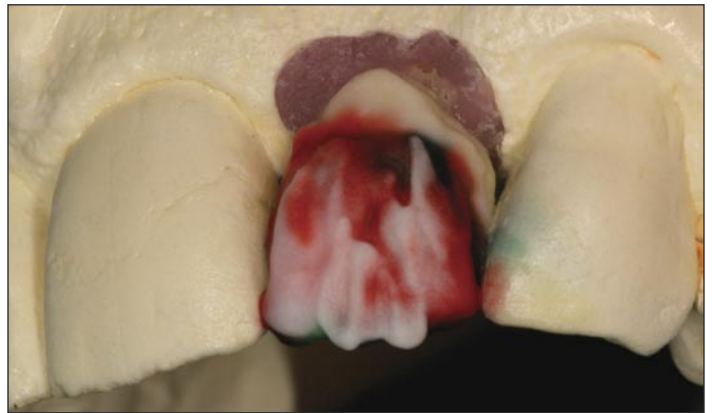

Fig. 14

Cervical Translucent (Fig 9) is placed around the gingival to give natural gingival shade. The Translucent Modifier (Fig 10) is used on the middle third to give effect. The mamelon effect (Fig 11) is layered on

the incisal third and than cover the almost the entire crown with Clear Fluorescence powder (Fig 12 & 13). A Translucent Neutral (Fig 14) is applied on the incisal for effect.

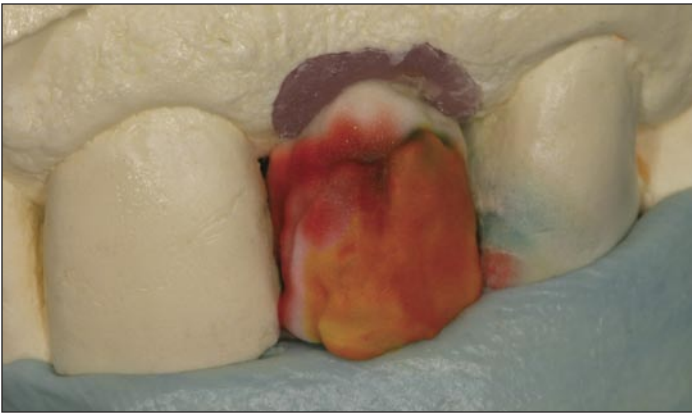

Fig.15

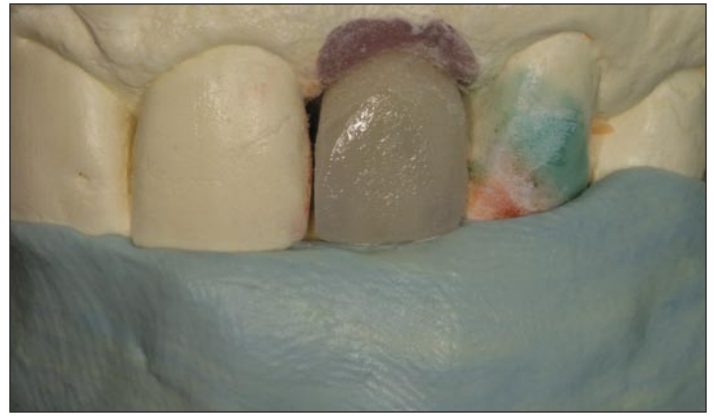

Fig.16

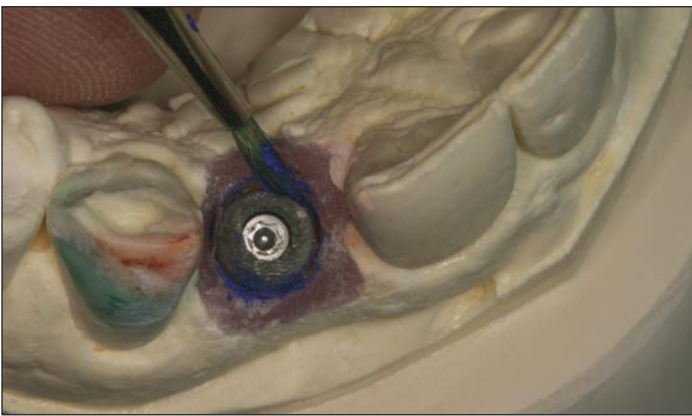

Fig.17

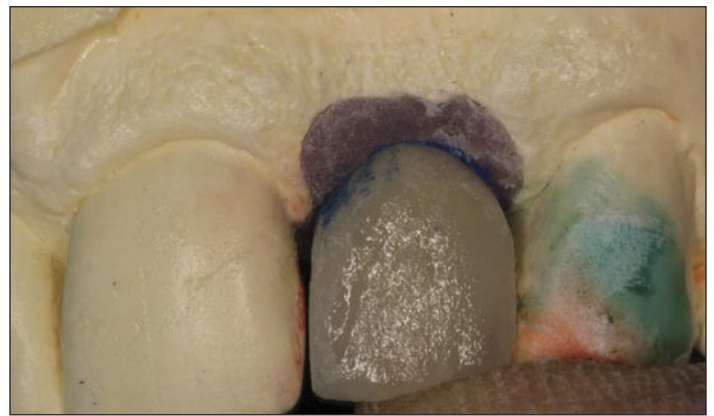

Fig.18

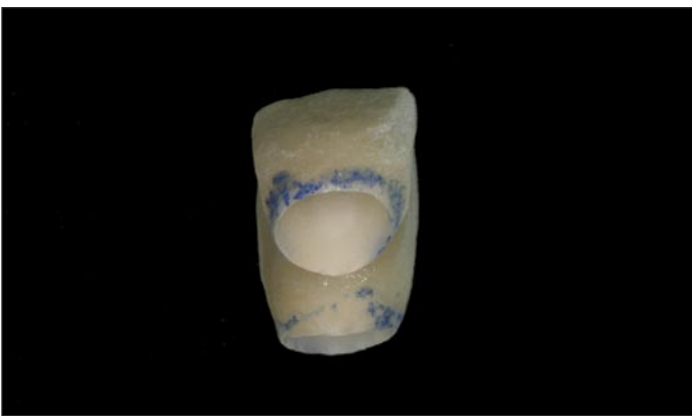


Fig.19

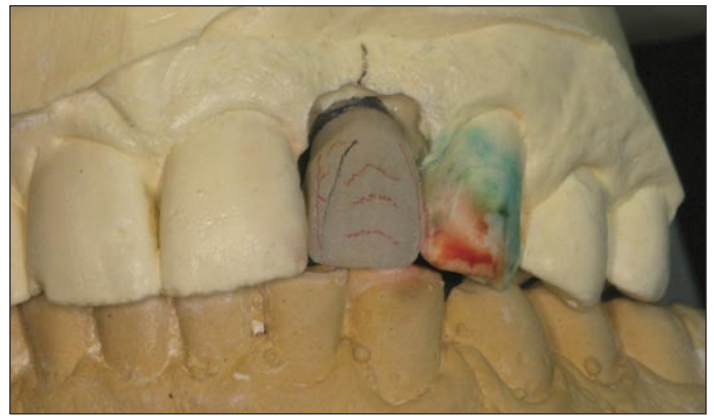


Fig.20

The facial is covered with Enamel Incisal (Fig 15) which will create a yellow hue. After the first bake (Fig 16) the restoration is checked using the putty matrix.

The crown build up will have uneven area at the gingival and can be impinging the tissue. You can mark the soft tissue on the master model (Fig 17) with a marker. The restoration can be checked for fit (Fig 18) to the gingival and the marker will show the areas that are hitting hard (Fig 19).

An anterior tooth is more obvious and the surface texture will affect the appearance of the crown blending in with the natural dentition. The surface texture (Fig 20) is completed; it is composed of horizontal and vertical concavities that vary in complexity and intensity.

To assure that the abutment fits the same in the mouth as on the dental technicians master model, a matrix (Fig 21) is fabricated with GC Pattern Resin. The resin is applied on the abutment and the incisal and occlusal surface of the adjacent teeth.

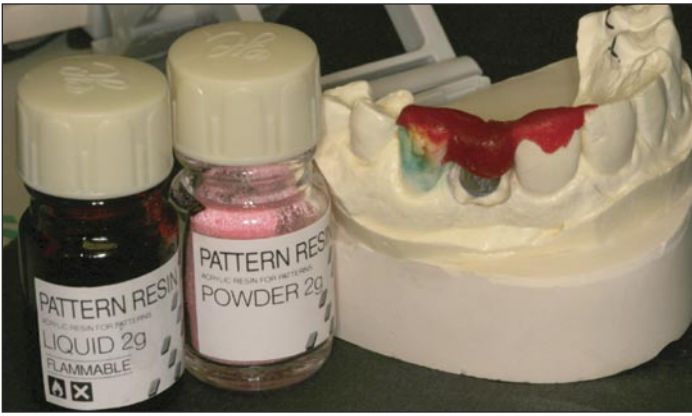

Fig.21

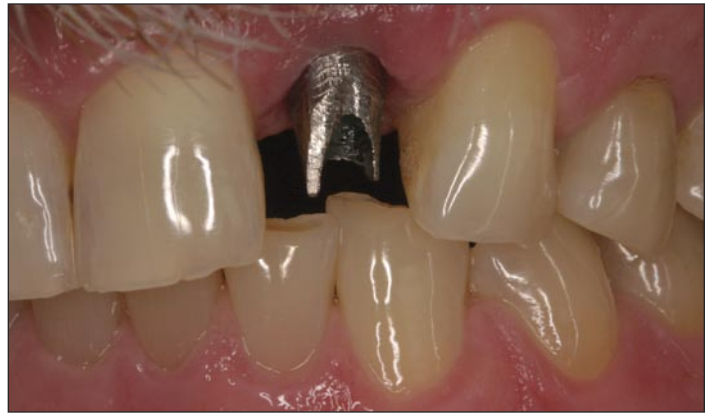

Fig.22

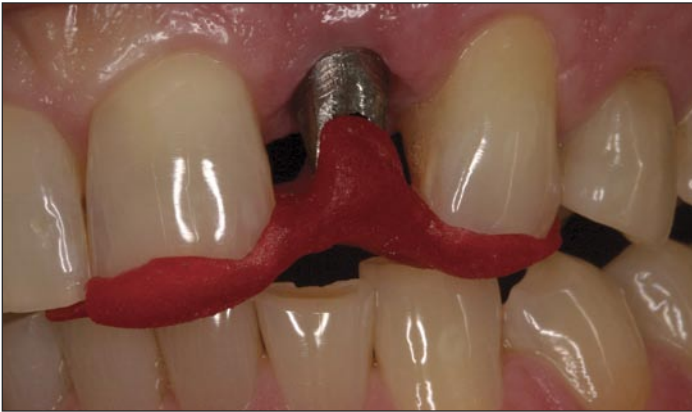

Fig. 23

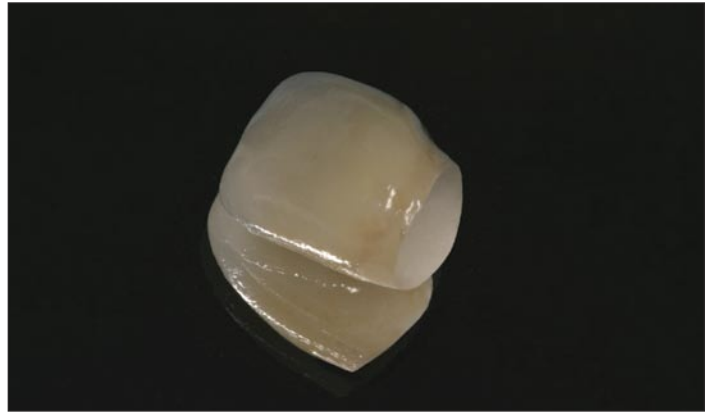

Fig.24

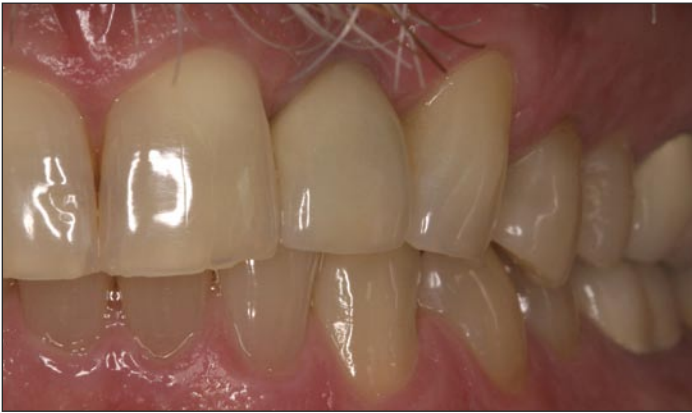

Fig.25

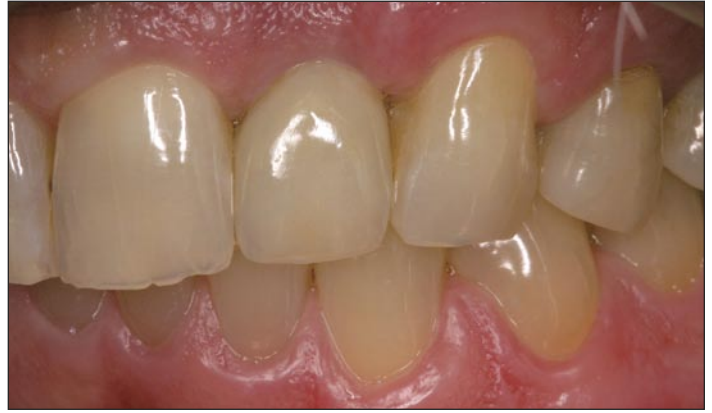

Fig.26

Placement Of The Implant And Crown

The implant abutment is placed (Fig 20) and the pattern resin matrix (Fig 23) is used to check the fit of the abutment. The Procera Zirconium restoration (Fig 24) is then ready for placement.

The final restoration (Fig 25) is checked and then cemented into place giving the patient (Fig 26) a precision implant abutment with the high esthetics of an all ceramic restoration.

Conclusion

Today the patient's education on dentistry and especially the esthetics that can be accomplished is apparent. They may consider the cost is

higher but they are looking for the results.

Dental Implants are a big part of the patient's education and we are doing more implants today than ever. All ceramic restorations are accepted and in fact should be the first choice for most anterior crowns. The anterior restorations are looked at for their esthetic properties, while posterior is primarily for their strength.

Together Implants and All Ceramics are efficient and give a quality dental restoration. The benefits these applications give are directly seen by the patient. The dental professional should look to restore with the most conservative restoration satisfying patient's esthetic and function. This is accomplished with the Precision of Implants and the Esthetics of All-Ceramics.