

Improving Endodontic Success through Coronal Leakage Prevention

Gregori M. Kurtzman, DDS, MAGD, FACD, DICOI

Introduction

Endodontic failure has been associated with coronal leakage within the canal system following obturation. The literature suggests that coronal leakage is far more likely a determinant of clinical success or failure than apical leakage.¹ Recent advances in resin obturation materials have been shown to provide superior sealing of the canal system but without addressing the coronal aspect of the tooth, failure endodontically may occur. Studies confirm that a sound coronal seal is of paramount importance to the overall success of root canal treatment.^{2,3} Regardless of the obturation method the best rule is: a properly cleaned, shaped, and

obtured tooth should be permanently restored as soon as possible.⁴

No matter what our intentions are following obturation of the canal system, patients may delay restoration of the tooth that has been treated. Financial and time constraints often influence when the final restoration is completed. Additionally, between visits an adhesive material will prevent leakage and contamination of the canal.

Coronal leakage

Coronal leakage has been indicated in the literature as the major determinant of endodontic success or failure. No matter what we place in the canal, if the coronal portion of the tooth is not sealed with materials that bond to tooth structure and are resistant to dissolution by oral fluids, then, over time endodontic failure may be inevitable.

It is not unusual to have a patient present with decay at the margin of a crown of a tooth that had prior endodontic therapy. Because the tooth was treated endodontically, sensitivity that may indicate a problem under the crown will not alert the patient to seek dental care. Coronal leakage for even a minimal amount of time may quickly lead to apical migration of bacteria. When the patient does present coronal leakage may have been ongoing for an extended period of time complicating treatment or rendering the tooth non-restorable necessitating extraction.

The literature indicates significant coronal dye and bacterial leakage following exposure of sealed root canals to artificial and natural saliva leading to complete bacterial leakage may occur within 2 days.⁵ Supported in an invitro study, found that dye leakage can occur in as little as three (3) days.⁶ It has been suggested that gutta-percha does not offer an effective barrier to crown-down leakage when exposed to the oral environment.⁷ Additional studies using gutta percha and various sealers, indicate that gutta percha will allow bacterial leakage. But use of an adhesive sealer can significantly slow or stop coronal-apical bacterial migration.⁸

The predominant bacteria found in root-filled teeth with coronal leakage and persistent apical periodontitis is the Gram-positive facultative anaerobe *Staphylococcus*. This is followed by the groups *Streptococcus* and *Enterococcus*; all normal salivary flora.⁹ Coronal leakage provides a constant source of microorganisms and nutrients that initiate and maintain periradicular inflammation and may well be the largest cause of failure in endodontic therapy.¹⁰

Endodontic obturation materials do not prevent coronal microleakage for an indefinite period of time.¹¹ In a sample of 937 root filled teeth which had not received restorative treatment during the previous year, the data showed that the technical standard of both coro-

nal restoration and root filling were essential to periapical health.¹² It is not uncommon for coronal leakage to occur following root canal treatment as a result of the presence of a deficient composite resin fillings and secondary caries under restorations.¹³

Yet the endodontic materials utilized over the past fifty (50) years have shown that they do not prevent coronal leakage when challenged. In yet another investigation, forty-five root canals were cleaned, shaped, and then obturated with gutta-percha and root canal sealer, using a lateral condensation technique. The coronal portions of the root filling materials were placed in contact with *Staphylococcus epidermidis* and *Proteus vulgaris*. The number of days required for these bacteria to penetrate the entire root canals was determined. Over 50% of the root canals were completely contaminated after 19-day exposure to *S. epidermidis*. Fifty percent of the root canals were also totally contaminated when the coronal surfaces of their fillings were exposed to *P. vulgaris* for 42 days.¹⁴ When comparing AH-26 and other commonly used sealers after 45 days exposure to the oral cavity, none of the sealers was capable of preventing leakage and coronal dye penetration.¹⁵ So we can see that the quality of both the coronal restoration and obturation material are essential to periapical health as none of the present-day root canal sealers may hermetically seal "the root canal wall—gutta percha filling interface". In this respect the importance of perfectly sealing coronal restorations (both temporary and permanent) needs to be emphasized.¹⁶

Pre-Endodontic Therapy Buildups (Canal Projection)

Coronal leakage is a major contributor to Endodontic failure.¹⁷ A bonded core placed prior to disinfection and obturation of the canal system of the tooth can greatly diminish the leakage potential both during and after Endodontic therapy.

Isolation of the pulp chamber can be a challenging task when minimal coronal structure remains and Endodontic therapy is required as part of the oral rehabilitation (Fig. 1). Coronal reinforcement has traditionally been addressed following the Endodontic phase. But a coronal bonded buildup can simplify the Endodontic phase and strengthen the tooth, decreasing the possibility of further damage to the tooth due to the dam clamp or mastication before a full coverage restoration can be placed. The Canal Projector core allows isolation of the individual canals by surrounding them with a resin buildup (Fig. 2). Sealing the pulpal floor and area surrounding the canal orifices also will decrease coronal leakage potential during and following endodontic treatment.

Following identification of the canal orifices and caries removal, a Canal Projector cone (CJ Engineering, Santa Barbara, CA—www.cjengineering.com) is placed on a hand file and inserted into each canal. A dentin adhesive is placed on all exposed surfaces and light cured. This is followed by injection of a dual-cure buildup material around the projector cones. When set of the buildup material has been completed the handfiles and projectors can be removed leaving straight-line access into each individual canal. Visualization of the orifice is elevated to the occlusal plane instead of deep within the tooth and a bonded seal coronally around each orifice is achieved. Should the restoring dentist wish to place posts in to the tooth, post space preparation is simplified and misdirection of the post preparation is minimized.

Coronal Restoration (Access sealing)

Microorganisms can penetrate through different temporary restorative materials and supposedly well obturated root canals. The use of adhesive sealers may, play an important role by minimizing coronal leakage. In addition the importance of an immediate definitive coronal seal should be emphasized after obturation of the canal system.¹⁸⁻²⁰

Seventy extracted single-rooted mandibular premolars were studied to determine the length of time needed for bacteria present in natural human saliva to penetrate through three commonly used temporary restorative materials and through the entire root canal system obturated with the lateral condensation technique. The average time for broth contamination of access cavities closed with gutta percha (7.85 days), IRM (12.95 days) and Cavit-G (9.80 days) indicating that even in the short periods of time normally permitted between visits, complete leakage may result. IRM, long a common temporary material was shown to leak to a significantly higher degree than glass ionomers.²¹ Glass-ionomer cement due to its adhesive nature may prevent bacterial penetration to the periapex of root-filled teeth over a 1-month period as compared to IRM or Cavit temporary restorations.²² Another important consideration with regard to the temporary restoration's ability to prevent coronal leakage is how the material behaves under mechanical load and thermocycling. Non-adhesive temporaries show an increased percentage of marginal breakdown and increased microleakage after thermocycling and loading. There was no significant improvement with increased thickness of the temporary material.²³⁻²⁵ When crowns were sealed with IRM, recontamination was detected within 13.5 days in the canals medicated with chlorhexidine, after 17.2 days in the group

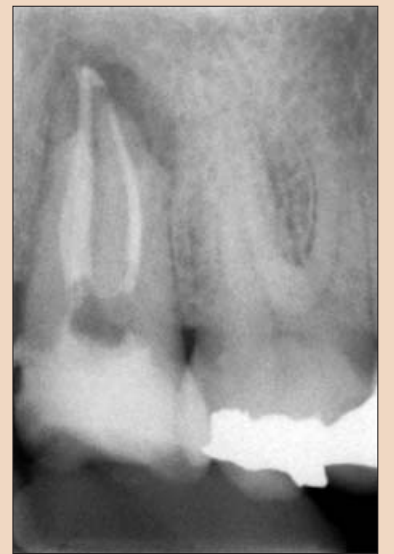

Fig. 4: Placement of an immediate coronal restoration with Fugix IX™ (GC America, Alsip, IL) glass ionomer following endodontic therapy with evident periapical lesion. (Courtesy of Dr. Martin Trope).

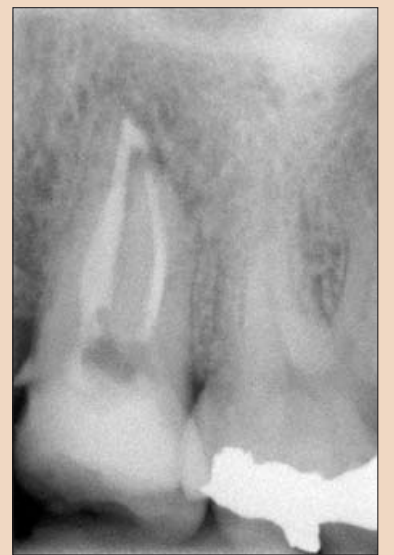

Fig. 5: Coronal seal has been maintained allowing apical healing of periapical lesion one year following treatment. (Courtesy of Dr. Martin Trope).

medicated with CaOH₂ and after 11.9 days in the group medicated with both chlorhexidine and CaOH₂. The group with no medication, but sealed with IRM, showed recontamination after 8.7 days. There were statistically significant differences between the teeth with or without coronal seal. The coronal seal delayed but did not prevent leakage of microorganisms.²⁶ Other studies, confirm that IRM started to leak after ten (10) days, whereas Cavit and Dyract leaked after two (2) weeks.²⁷

The use of a resin based temporary restorative material or glass ionomer over partially removed resin composite restorations could be beneficial in achieving better resistance to marginal leakage (Fig. 3). Maintaining partially removed permanent restorations does not seem to cause a problem with achieving marginal seal.²⁸ Glass ionomer provided a statistically better coronal seal than bonded composite or a bonded amalgam preventing bacterial apical migration.²⁹ This may be due to the glass ionomers ability to adhere to the sclerotic dentin found on the pulpal floor better than adhesive resins. The key seems to be, lock out the coronal

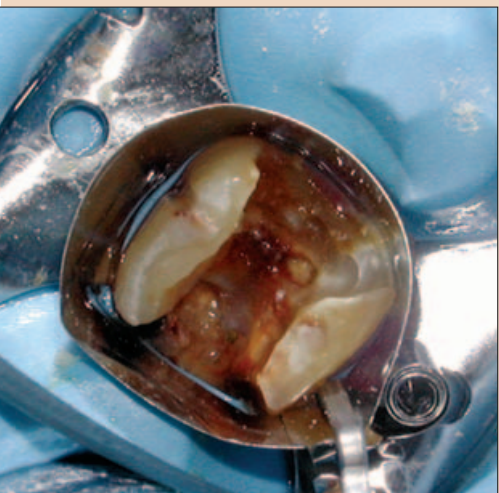

Fig. 1: Severe coronal breakdown of a lower molar requiring endodontic therapy.

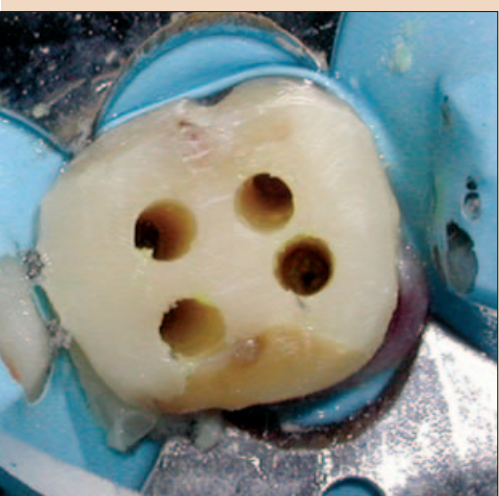


Fig. 2: Coronal pre-endodontic buildup achieved with Canal Projectors providing individual straight-line access into each canal.

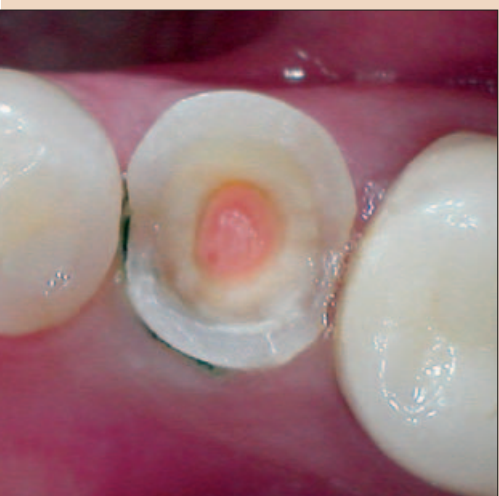

Fig. 3: Temporary restoration using the glass ionomer Fugix Triage™ Pink (GC America, Alsip, IL) to seal endodontic access. (Courtesy of Dr. Mark Grebosky).

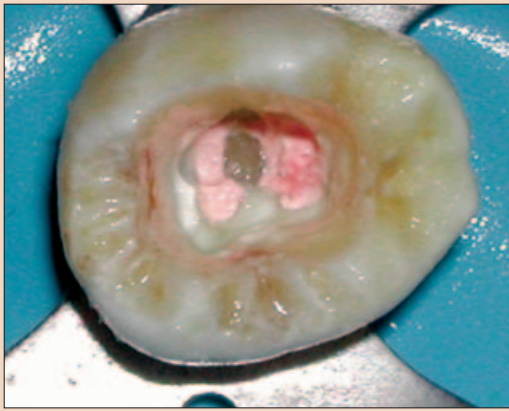


Fig. 6: The pulp chamber has been etched and an adhesive applied to all surfaces.

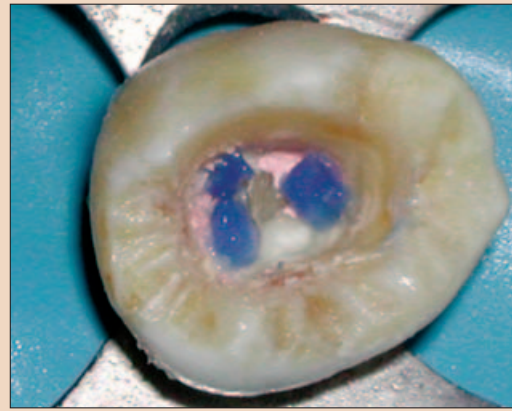


Fig. 7: To assist in locating the orifices later, a contrasting color light cure resin is applied over each orifice and cured.

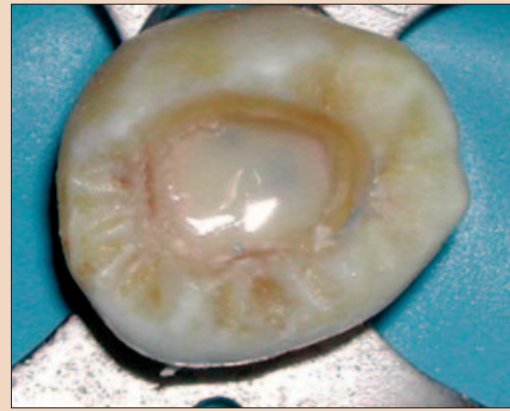


Fig. 8: The entire pulpal floor is covered by a flowable composite and cured.

authors have examined coronal microleakage with respect to gut-tapercha root fillings and coronal restorations, but few have investigated the coronal seal afforded by various post systems. The seal provided by a cemented post depends on the seal of the cement used. It appears that the dentine-bonding cements (adhesive resins and glass ionomers) have less microleakage than the traditional, non-dentine-bonding cements (i.e. zinc phosphates and polycarboxylates).³⁶

→ DT page 22

bacteria and the apical area will heal (Fig. 4 and 5)

Mineral Trioxide Aggregate (MTA) has since its introduction a few years ago been advocated as a sealing material especially when perforation has occurred. But an investigation found mild inflammation was observed in 17% and 39% of the roots with and without an orifice plug, respectively without development of severe inflammation, the sealing efficacy of MTA orifice plugs could not be determined.³⁰

Should amalgam be the material of choice for the dentist, a bonded amalgam produced significantly less leakage than did the non-bonded amalgams. To prevent the reinfection of the endodontically treated molar, it may be preferable to restore the tooth immediately after obturation by employing a bonded amalgam coronal-radicular technique.³¹ Whereas, core buildup or access closure, with adhesive materials has shown good long term leakage resistance. The "sandwich" technique (GI base with overlaying composite) and the composite resin restorations allowed significantly less coronal leakage than glass ionomer cement restorations. This may be because the composite resin prevents salivary dissolution of the glass ionomer long term.³²

Results indicate that the sealing ability of adhesive and flowable materials can decrease coronal leakage potential.³³ Because of the risk of coronal microleakage, endodontically treated teeth should be restored as quickly as possible.³⁴ It is more prudent to use a permanent restorative material for provisional restorations to prevent inadequate canal sealing and the resulting risk of fluid penetration.³⁵ To minimize the potential of perforation when reentering the tooth to place either a post or to retreat endodontically, placement of a contrasting colored resin over each orifice may be beneficial. This is followed by covering the entire pulpal floor with a tooth colored flowable resin (Figs. 6, 7 and 8). These are available in a multitude of easily identifiable colored flowable composites. Available in pink (PermaFlo® Pink) or purple (PermaFlo® Purple) from Ultradent (South Jordan, UT), dark red (Flow-it dark gingival) from Pentron Clinical Technologies (Wallingford, CT) or dark blue from DenMat (Santa Maria, CA).

Coronal microleakage has received considerable attention as a factor related to failure of endodontic treatment and much emphasis is placed on the quality of the final restoration. Intracanal posts are frequently used for the retention of coronal restorations. Many

36 Risk Management Modules from Dental Protection

Dental Protection is the largest indemnity organisation of its kind with 48,000 members in over 70 countries worldwide.

We have used our vast wealth of experience and knowledge to create 36 easy-to-read risk management modules to help the whole dental team reduce risk within their day-to-day practice.

The risk management modules will be available to download internationally in the very near future. If you would like further information on how to purchase the modules please send your name and e-mail address to lyne.moorcroft@mps.org.uk

- | | | |
|---|--|------------------------------|
| 1) Periodontal disease | 14) Under-treatment & supervised neglect | 27) The compromised tooth |
| 2) Endodontics | 15) Histories | 28) Computerised records |
| 3) Trauma | 16) Composites | 29) Alternative orthodontics |
| 4) Third molars | 17) Sedation | 30) Amalgam-free practice |
| 5) Crown and bridge | 18) Overtreatment | 31) Minor oral surgery |
| 6) Orthodontics | 19) Treating children | 32) Preventive dentistry |
| 7) Full dentures | 20) Clinical records | 33) Accidental injury |
| 8) Adhesive dentistry | 21) The emergency patient | 35) Elective treatment |
| 9) Complaint handling | 22) Cross infection control | 35) Drugs and prescribing |
| 10) Implants | 23) Radiographs | 36) Patients at risk |
| 11) Margins of error (fixed prosthodontics) | 24) Oral cancer | |
| 12) Complex cases (treatment planning) | 25) Cosmetic dentistry | |
| 13) Case assessment | 26) Partial dentures | |



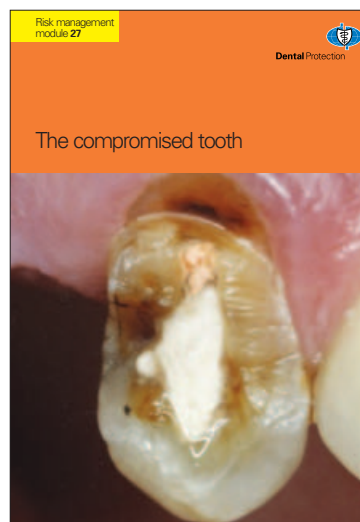
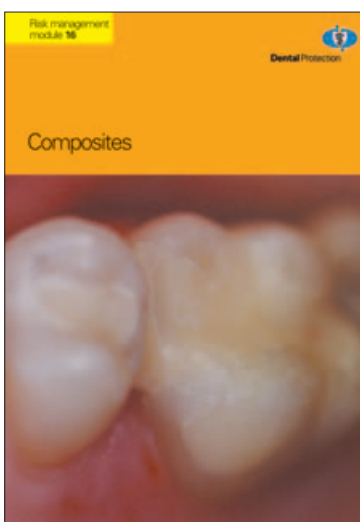
Case assessment
Patient input
Clinical examination and tests
Diagnosis
Treatment plan

Every patient has their own unique dental needs. It is the dentist's responsibility to ensure that the patient's dental care is tailored to their individual requirements. This module provides a comprehensive guide to the case assessment process, from patient input to the final treatment plan.

Key topics covered:

- Understanding patient needs and expectations
- Conducting a thorough clinical examination
- Utilizing diagnostic tests and radiographs
- Formulating a clear diagnosis and treatment plan
- Communicating the plan to the patient

This module is essential for ensuring high-quality patient care and minimizing the risk of complications.



The compromised tooth
A considerable proportion of the dental problems in restorative dentistry and prosthodontics arise in connection with the restoration of compromised teeth.

This module provides a detailed overview of the challenges associated with restoring compromised teeth, including the identification of the problem, the selection of the appropriate restorative material, and the execution of the restoration.

Key topics covered:

- Identifying and classifying compromised teeth
- Assessing the extent of the damage
- Choosing the most suitable restorative option
- Preparing the tooth for restoration
- Executing the restoration with precision

This module is a critical resource for dentists seeking to improve their skills in managing compromised teeth.

← DT page 21

Resin-supported polyethylene fiber and glass fiber dowels showed the lowest coronal leakage when compared with stainless steel and zirconia dowels. This may be due to better adhesion of the luting agent to these resin impregnated posts than metal or ceramic posts which do not allow adhesive penetration into the surface of the post. There were no significant differences between resin-supported polyethylene fiber and glass fiber dowels at any time period. The initial leakage measurement in zirconia dowel and stainless steel dowels were similar but became significantly different at 3 and 6 months. Resin-supported polyethylene fiber dowels and glass fiber dowels tested exhibited less microleakage compared to zirconia dowel systems.³⁷

Cleansing the Canal (Smear Layers)

Coronal sealing ability is not the only factor to influence the seal of the canal and prevent apical leakage. How well the sealer adheres to the canal walls is also important. Smear layer can play a factor which may prevent sealer penetration into the dentinal tubules. The frequency of bacterial penetration through teeth obturated with intact smear layer (70%) was significantly greater than that of teeth from which the smear layer had been removed (30%). Removal of the smear layer enhanced sealability as evidenced by increased resistance to bacterial penetration.³⁸ The incidence of apical leakage was reduced in the absence of the smear and the adaptation of gutta-percha was improved no matter what obturation method was used later.³⁹⁻⁴¹ However, regardless of the obturation technique (Thermoplastized, lateral or vertical condensation or single cone) when a non-adhesive sealer was used leakage increased after 30 days.⁴²

What is used to obturate the canals is important, however the manner in which the canal was prepared prior to obturation also determines how well the canal is sealed when therapy is completed. Rotary instrumentation with NiTi files has shown less microleakage than hand instrument prepared canals irrespective of what was used to obturate the canal.⁴³ The machining of the canal walls with NiTi rotary instruments provides smoother canal walls and shapes that are easier to obturate than can be achieved with stainless steel files. The better the adaptation of the obturation material to the instrumented dentinal walls, the less leakage is to be expected along the entire root length. The better the canal walls are prepared, the more smear layer and organic debris is removed which is beneficial to root canal sealing.

Smear layer removal is best achieved by irrigating the canals with NaOCl (sodium hypochlorite) followed by 17% EDTA solution.⁴⁴ Whereas, the NaOCl dissolves the organic component of the smear layer exposing the dentinal tubules lining the canal walls. EDTA, a chelating agent, dissolves the inorganic portion of the dentin opening the dentinal tubules. Alternating between the two irrigants as the instrumentation is being performed will permit removal of

more organic debris further into the tubules, increasing resistance to bacterial penetration once the canal is obturated.^{45,46}

Obturation

The purpose of the obturation phase of an endodontic therapy is two-fold; to prevent microorganisms from re-entering the root canal system, and to isolate any microorganisms that may remain within the tooth from nutrients in tissue fluids. No matter how well we seal the canal, if the coronal portion of the tooth is not thoroughly sealed then bacterial leakage may be a matter of time. Accessory canals may be present in the pulp chamber leading to the furcation area. This may be an additional source of leakage that often goes unaddressed either following obturation of the canals or during the restorative phase. Placement of a layer of resin-modified glass ionomer cement or adhesive resin to seal this area immediately following obturation can prevent leakage prior to final restoration of the tooth.⁴⁷ But, it must always be remembered that success will only be achieved if the root canal system has been as thoroughly debrided as possible of infected material. Irrigation is key, to removal of this smear layer lining the canal walls.

The obturation material is a two pronged sword. What sealer is used is as important as which core material is placed within the canal. Gutta percha has limitations in resistance to coronal leakage which have been overcome with the newer resin alternatives. Although sealers can form close adhesion to the root canal wall, none is able to bond to the gutta percha core material. Upon setting, shrinkage of the sealer allows the sealer to pull away from the gutta percha core, leaving a microgap through which bacteria may pass.⁴⁸ Several alternatives are available for core material selection.

Resilon™, a resin gutta percha alternative that is bondable with methacrylic sealers such as Epiphany™ (Pentron Clinical Technologies, Wallingford, CT) and Real-Seal™ (SybronEndo, Orange, CA) was introduced three years ago after extensive studies. The core material Resilon™, is available in .02, .04 or .06 taper ISO sized cones from Pentron Clinical Technologies (Wallingford, CT) or SybronEndo (Orange CA) and as sized apical plugs (Lightspeed Technologies, San Antonio, TX).^{49,50} Resilon™ showed significantly less leakage than gutta percha. In studies performed at University of North Carolina, the gutta percha group demonstrated leakage in 80% of specimens when and was not dependant on obturation technique nor which sealer was used.⁵¹ Because of these limitations seen with gutta percha, the seal of a coronal restoration may be as important as the gutta percha fill in preventing reinfection of the root canal. Studies have shown that leakage of bacteria with Resilon™ is significantly reduced compared with gutta percha. The significance of this is should the coronal break down the adhesive obturation material may slow down or prevent apical migration of bacteria allowing healing to occur (Figs 9 and 10). An additional benefit when filling the canals with the new resin-

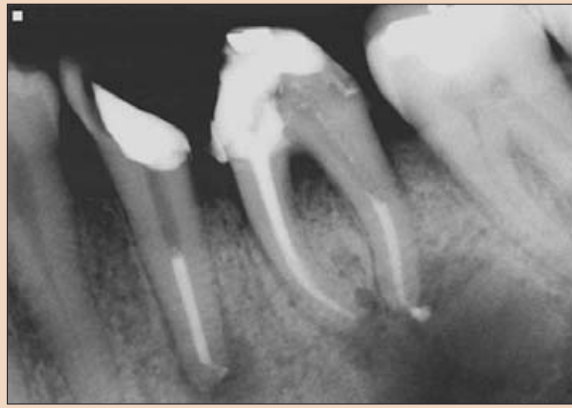

Fig. 9: Periapical lesions present associated with lower premolar and molar obturated with Resilon system at completion of endodontic treatment. (Courtesy of Dr. Joseph Maggio).

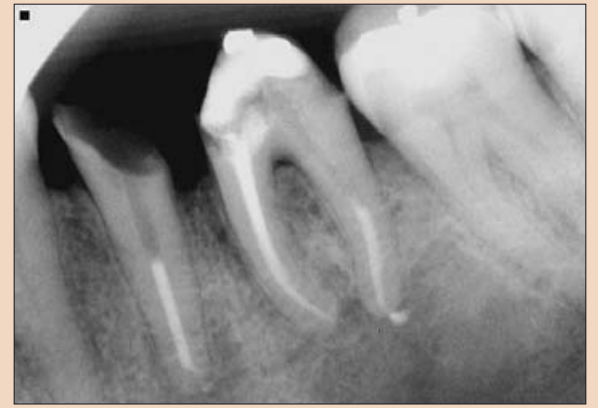

Fig. 10: Seven months post completion of endodontic treatment, showing loss of coronal restorations, yet apical lesions seen previously have resolved significantly. (Courtesy of Dr. Joseph Maggio).




Fig. 11: SEM demonstrating microgap formation with AH-26 epoxy sealer due to polymerization shrinkage. (ES - epoxy sealer, D - dentin).

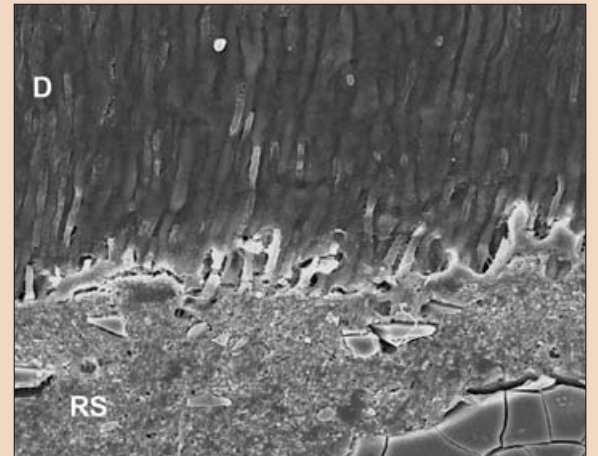


Fig. 12: SEM demonstrating intimate contact with methacrylic sealer and Resilon and dentinal tubula penetration of the sealer. (RS - methacrylic sealer, D - dentin).

based obturation material an increase was observed in the invitro resistance to fracture of endodontically treated single-canal extracted teeth when compared with standard gutta percha techniques. Resilon™ demonstrated a twenty-five (25) percent increase in root strength than gutta percha samples.⁵²

Fiber obturators, an alternative core material may be used when a post will be placed to strengthen the root and retain the coronal core. These allow obturation of the canal and placement of the post at the same step assuring coronal seal.^{53,54} Microbial leakage occurred more quickly in lateral and vertical condensation techniques compared with obturation with fiber obturation systems.⁵⁵ Currently two fiber obturator systems are commercially available; the FibreFill™ system (Pentron Clinical Technologies, Wallingford, CT) which was introduced in 2001 and the recently available InnoEndo™ system (HeraeusKulzer, Armonk, NY). Both systems use resin sealers allowing formation of a monoblock across the root to both strengthen and seal the canal system.

Sealer selection is very important to prevent microleakage and permit a bond to the core material. Zinc oxide and eugenol (ZOE) sealers has been a mainstay in endodontic therapy for over one hundred (100) years. When exposed to coronal leakage ZOE sealers demonstrated complete leakage by the second day. Results indicated that none of the ZOE formulations tested could predictably produce a fluid-tight seal even up to the fourth day.⁵⁶

AH-26, an epoxy sealer originally introduced forty (40) years ago was also unable to bond to gutta percha leading to coronal leakage issues. Leakage with AH-26 was not dependant on obturation technique showing gross leakage increasing within the first four (4) months following obturation when coronally challenged. Coronal

leakage was significantly greater during the first 4 months.⁵⁷ Complete bacterial leakage with AH-26 may be seen in as few as 8.5 weeks should the coronal restoration permit leakage.⁵⁸

Additionally, invitro studies found gutta percha and AH-26 or AH-26 plus permitted leakage of both bacteria and fungi. Leakage in experimental teeth occurred between 14 and 87 days, with 47% of the samples showing leakage. AH26 sealer permitted bacterial leakage in 45% and fungi leakage in 60% samples. Whereas, the samples with AH Plus, demonstrated bacterial leakage in 50% and fungi 55% of the samples. There was no statistically significant difference in penetration of bacteria and fungi between the two versions of the sealer.⁵⁹ Comparative studies looking at periapical inflammation between teeth treated with gutta percha with AH-26 sealer and Resilon with methacrylic sealer found statistically less inflammatory response with the Resilon treated teeth. Mild inflammation was observed in 82% of roots filled with gutta percha and AH-26 sealer compared with 19% of Resilon treated teeth. The monoblock provided by the Resilon system was associated with less apical periodontitis, which may be because of its superior resistance to coronal microleakage.⁶⁰ As AH-26 is unable to bond to gutta percha, polymerization shrinkage of the epoxy resin can result in a microgap leading to the leakage reported in the literature (Fig. 11). Alternatively, the bond reported between the methacrylic sealer (Epiphany or Real-Seal) and Resilon is sufficient to prevent microgap formation as the sealer polymerizes (Fig. 12).

Electrophoresis leakage studies recently completed at University of Maryland comparing gutta percha with AH-26 sealer and Resilon™ with Epiphany™ sealer found significant differences in leakage resistance. The gutta percha/AH-26 group demonstrated an

average resistance of 404.6 micro amps with one hundred (100) percent of the samples leaking compared to an average resistance of 27.7 micro amps with sixty (60) percent showing some leakage. The lower the value of resistance in micro amps, the more resistant the specimen was to leakage.⁶¹ These results support other studies indicating that gutta percha and AH-26 when challenged do not offer resistance to coronal leakage. Should the practitioner wish to continue using these materials a permanent restoration needs to be placed at the appointment when endodontic therapy is completed.

Conclusion

Of 41 articles published between 1969 and 1999 (the majority from the 1990s) the literature suggests that the prognosis of root canal-treated teeth can be improved by sealing the canal and minimizing the leakage of oral fluids and bacteria into the periradicular areas as soon as possible after the completion of root canal therapy.⁶²

Endodontic success is a multifactorial issue. Like a jigsaw puzzle, the full picture can only be seen when all the pieces are fit together. How the canals are instrumented is as important as what is used to obturate the canal system. This is also influenced by what is placed coronally and when the coronal aspect is sealed. NiTi rotary instruments and an irrigation protocol that includes NaOCl and EDTA will maximize the sealing ability of glass ionomer or the newer methacrylic resin sealers. The last piece of the puzzle, sealing coronally should be performed with adhesive permanent restorative materials immediately at the conclusion of the first endodontic appointment to prevent apical migration of bacteria and assure sealability of the canals. □

References

1. Sritharan A.: Discuss that the coronal seal is more important than the apical seal for endodontic success. Aust Endod J. 2002 Dec;28(3):112-5.

2. Begotka BA, Hartwell GR.: The importance of the coronal seal following root canal treatment. *Va Dent J.* 1996 Oct-Dec;73(4):8-10

3. Siqueira JF Jr, Roca IN, Favieri A, Abad EC, Castro AJ, Gahyva SM.: Bacterial leakage in coronally unsealed root canals obturated with 3 different techniques. *Oral Surg Oral Med Oral Pathol Oral Radiol Endod.* 2000 Nov;90(5):647-50

4. Pommel L, Camps J.: In vitro apical leakage of system B compared with other filling techniques. *J Endod.* 2001 Jul;27(7):449-51

5. Khayat A, Lee SJ, Torabinejad M.: Human saliva penetration of coronally unsealed obturated root canals. *J Endod.* 1993 Sep;19(9):458-61.

6. Swanson K, Madison S.: An evaluation of coronal microleakage in endodontically treated teeth. Part I. Time periods. *J Endod.* 1987 Feb;13(2):56-9.

7. Cohen S, Burns R.: *Pathways to the Pulp.* 8th edition, CV Mosby, New York, 2001.

8. Britto LR, Grimaudo NJ, Vertucci FJ.: Coronal microleakage assessed by polymicrobial markers. *J Contemp Dent Pract.* 2003 Aug 15;4(3):1-10.

9. Adib V, Spratt D, Ng YL, Gulabivala K.: Cultivable microbial flora associated with persistent periapical disease and coronal leakage after root canal treatment: a preliminary study. *Int Endod J.* 2004 Aug;37(8):542-51.

10. J.E. Leonard; J.L. Gutmann; I.Y. Guo.: Apical and coronal seal of roots obturated with a dentine bonding agent and resin. *Inter Endod J* 1996 29:76-83

11. Pisano D; DiFiore P; McClanahan S; Lautenschlager E; Duncan J.: Intracanal Sealing of Gutta-Percha Obturated Root Canal to Prevent Coronal Microleakage. *J Endod* 1998 Oct;10.

12. De Moor R, Coppens C, Hommez G.: Coronal leakage reconsidered. *Rev Belge Med Dent.* 2002;57(3):161-85.

13. Chong BS.: Coronal leakage and treatment failure. *J Endod.* 1995 Mar;21(3):159-60.

14. Torabinejad M, Ung B, Kettering JD.: In vitro bacterial penetration of coronally unsealed endodontically treated teeth. *J Endod.* 1990 Dec;16(12):566-9.

15. Kopper PM, Figueiredo JA, Della Bona A, Vanni JR, Bier CA, Bopp S.: Comparative in vivo analysis of the sealing ability of three endodontic sealers in post-prepared root canals. *Int Endod J.* 2003 Dec;36(12):857-63.

16. De Moor R, Coppens C, Hommez G.: Coronal leakage reconsidered. *Rev Belge Med Dent.* 2002;57(3):161-85. De Moor R, Hommez G.: The importance of apical and coronal leakage in the success or failure of endodontic treatment. *Rev Belge Med Dent.* 2000; 55(4):334-44.

17. Kurtzman GM.: Restoring Teeth with Severe Coronal Breakdown as a Prelude to Endodontic Therapy. *Endodontic Therapy*, 2004.

18. Imura N, Otani SM, Campos MJA, Jardim EG, Zuolo ML.: Bacterial penetration through temporary restorative materials in root-canal-treated teeth in vitro. *Inter Endod J* 1997 30:381-385

19. Uranga A, Blum JY, Esber S, Parahy E, Prado C.: A comparative study of four coronal obturation materials in endodontic treatment. *J Endod.* 1999 Mar;25(3):178-80.

20. Fox K, Gutteridge DL.: An in vitro study of coronal microleakage in root-canal-treated teeth restored by the post and core technique. *Int Endod J* 1997 Nov;30(6):361-8

21. Barthel CR, Zimmer S, Wussogk R, Roulet JF.: Long-Term bacterial leakage along obturated roots restored with temporary and adhesive fillings. *J Endod.* 2001 Sep;27(9):559-62

22. Barthel CR, Strobach A, Briedigkeit H, Gobel UB, Roulet JF.: Leakage in roots coronally sealed with different temporary fillings. *J Endod.* 1999 Nov;25(11):731-4

23. Mayer T, Eickholz P.: Microleakage of temporary restorations after thermocycling and mechanical loading. *J Endod.* 1997 May;23(5):320-2

24. Deveaux E, Hildebert P, Neut C, Boniface B, Romond C.: Bacterial microleakage of Cavit, IRM, and TERM. *Oral Surg Oral Med Oral Pathol.* 1992 Nov; 74(5):634-43

25. Deveaux E, Hildebert P, Neut C, Romond C.: Bacterial microleakage of Cavit, IRM, TERM, and Fermit: a 21-day in vitro study. *J Endod.* 1999 Oct; 25(10):653-9

26. Gomes BP, Sato E, Ferraz CC, Teixeira FB, Zaia AA, Souza-Filho FJ.: Evaluation of time required for recontamination of coronally sealed canals medicated with calcium hydroxide and chlorhexidine. *Int Endod J.* 2003 Sep; 36(9):604-9.

27. Balto H.: An assessment of microbial coronal leakage of temporary filling materials in endodontically treated teeth. *J Endod.* 2002 Nov;28(11):762-4.

28. Tulunoglu O, Uctasli MB, Ozdemir S.: Coronal microleakage of temporary restorations in previously restored teeth with amalgam and composite. *Oper Dent.* 2005 May-Jun;30(3):331-7.

29. Nup C, Boylan R, Bhagat R, Ippolito G, Ahn SH, Erakin C, Rosenberg PA.: An evaluation of resin-ionomers to prevent coronal microleakage in endodontically treated teeth. *J Clin Dent.* 2000;11(1):16-9.

30. Mah T, Basrani B, Santos JM, Pascon EA, Tjaderhane L, Yared G, Lawrence HP, Friedman S.: Periapical inflammation affecting coronally-inoculated dog teeth with root fillings augmented by white MTA orifice plugs. *J Endod.* 2003 Jul;29(7):442-6.

31. Howdle MD, Fox K, Youngson CC.: An in vitro study of coronal microleakage around bonded amalgam coronal-radicular cores in endodontically treated molar teeth. *Quintessence Int.* 2002 Jan;33(1):22-9.

32. Kleitches AJ, Lemon RR, Jeansonne BG.: Coronal microleakage in conservatively restored endodontic access preparations. *J Tenn Dent Assoc.* 1995 Jan;75(1):31-4.

33. Shindo K, Kakuma Y, Ishikawa H, Kobayashi C, Suda H.: The influence of orifice sealing with various filling materials on coronal leakage. *Dent Mater J.* 2004 Sep;23(3):419-23.

34. de Souza FD, Pecora JD, Silva RG.: The effect on coronal leakage of liquid adhesive application over root fillings after smear layer removal with EDTA or Er:YAG laser. *Oral Surg Oral Med Oral Pathol Oral Radiol Endod.* 2005 Jan;99(1):125-8.

35. Uranga A, Blum JY, Esber S, Parahy E, Prado C.: A comparative study of four coronal obturation materials in endodontic treatment. *J Endod.* 1999 Mar;25(3):178-80.

36. Ravanshad S, Ghoreeshi N.: An in vitro study of coronal microleakage in endodontically-treated teeth restored with posts. *Aust Endod J.* 2003 Dec; 29(3):128-33.

37. Usumez A, Cobankara FK, Ozturk N, Eskitascioglu G, Belli S.: Microleakage of endodontically treated teeth with different dowel systems. *J Prosthet Dent.* 2004 Aug;92(2):163-9.

38. Behrend GD, Cutler CW, Gutmann JL.: An in-vitro study of smear layer removal and microbial leakage along root-canal fillings. *Int Endod J.* 1996 Mar;29(2):99-107

39. Karagoz-Kucukay I, Bayirli G.: An apical leakage study in the presence and absence of the smear layer. *Int Endod J.* 1994 Mar;27(2):87-93

40. Saunders WP, Saunders EM.: Influence of smear layer on the coronal leakage of Thermafil and laterally condensed gutta-percha root fillings with a glass ionomer sealer. *J Endod.* 1994 Apr;20(4):155-8.

41. Gencoglu N, Samani S, Gunday M.: Dentinal wall adaptation of thermoplasticized gutta-percha in the absence or presence of smear layer: a scanning electron microscopic study. *J Endod.* 1993 Nov;19(11):558-62

42. Pommel L, Camps J.: In vitro apical leakage of system B compared with other filling techniques. *J Endod.* 2001 Jul;27(7):449-51

43. von Fraunhofer JA, Fagundes DK, McDonald NJ, Dumsha TC.: The effect of root canal preparation on microleakage within endodontically treated teeth: an in vitro study. *Int Endod J.* 2000 Jul;33(4):355-60.

44. Behrend GD, Cutler CW, Gutmann JL.: An in-vitro study of smear layer removal and microbial leakage along root-canal fillings. *Int Endod J* 1996 Mar;29(2):99-107.

45. Clark-Holke D, Drake D, Walton R, Rivera E, Guthmiller JM.: Bacterial penetration through canals of endodontically treated teeth in the presence or absence of the smear layer. *J Dent.* 2003 May;31(4):275-81.

46. Vivacqua-Gomes N, Ferraz CC, Gomes BP, Zaia AA, Teixeira FB, Souza-Filho FJ.: Influence of irrigants on the coronal microleakage of laterally condensed gutta-percha root fillings. *Int Endod J.* 2002 Sep;35(9):791-5.

47. Carrotte P.: Endodontics: Part 8. Filling the root canal system. *Br Dent J.* 2004 Dec 11;197(11):667-72.

48. Teixeira FB, Teixeira EC, Thompson J, Leinfelder KF, Trope M.: Dentinal bonding reaches the root canal system. *J Esthet Restor Dent.* 2004; 16(6):348-54.

49. Maggio JD.: RealSeal—the real deal. *Compend Contin Educ Dent.* 2004 Oct;25(10A):834, 836.

50. Chivian N.: Resilon—the missing link in sealing the root canal. *Compend Contin Educ Dent.* 2004 Oct;25(10A): 823-4, 826.

51. Shipper G, Orstavik D, Teixeira FB, Trope M.: An evaluation of microbial leakage in roots filled with a thermoplastic synthetic polymer-based root canal filling material (Resilon). *J Endod.* 2004 May;30(5):342-7.

52. Teixeira FB, Teixeira EC, Thompson JY, Trope M.: Fracture resistance of roots endodontically treated with a new resin filling material. *J Am Dent Assoc.* 2004 May;135(5):646-52.

53. Kurtzman GM, Jones OJ, Lopez L.: Predictable Endodontics: A fiber reinforced adhesively bonded endodontic obturator and post system. *Endodontic Therapy*, 2003.

54. Kurtzman GM, Jones OJ, Lopez L.: Fiberfill: A fiber reinforced adhesively bonded Endodontic obturator and post system. *Oral Health Journal*, 2003.

55. Shipper G, Trope M.: In vitro microbial leakage of endodontically treated teeth using new and standard obturation techniques. *J Endod.* 2004 Mar; 30(3):154-8.

56. Tewari S, Tewari S.: Assessment of coronal microleakage in intermediately restored endodontic access cavities. *Oral Surg Oral Med Oral Pathol Oral Radiol Endod.* 2002 Jun;93(6): 716-9.

57. De Moor RJ, Hommez GM.: The long-term sealing ability of an epoxy resin root canal sealer used with five gutta percha obturation techniques. *Int Endod J.* 2002 Mar;35(3):275-82.

58. Chailertvanitkul P, Saunders WP, MacKenzie D, Weetman DA.: An in vitro study of the coronal leakage of two root canal sealers using an obligate anaerobe microbial marker. *Int Endod J.* 1996 Jul;29(4):249-55.

59. Miletic I, Prpic-Mehicic G, Marsan T, Tambic-Andrasevic A, Plesko S, Karlovic Z, Anic I.: Bacterial and fungal microleakage of AH26 and AH Plus root canal sealers. *Int Endod J.* 2002 May;35(5):428-32.

60. Shipper G, Teixeira FB, Arnold RR, Trope M.: Periapical inflammation after coronal microbial inoculation of dog roots filled with gutta-percha or resilon. *J Endod.* 2005 Feb;31(2):91-6.

61. von Fraunhofer JA, Kurtzman GM, Norby CE.: Resin-based Sealing of Root Canals in Endodontic Therapy. Submitted for publication.

62. Helling I, Gorfil C, Slutzky H, Kopolovic K, Zalkind M, Slutzky-Goldberg I.: Endodontic failure caused by inadequate restorative procedures: review and treatment recommendations. *J Prosthet Dent.* 2002 Jun;87(6):674-8.

Author Info

Dr. Gregori Kurtzman is in private general practice in Silver Spring. He has lectured both nationally and internationally on the topics of Restorative dentistry, Endodontics and dental implant surgery and prosthetics and has had numerous journal articles published in peer reviewed publications. Dr. Kurtzman is on the editorial board of numerous publications. He is a consultant and clinical evaluator to multiple dental manufacturers. He has earned Fellowships in the Academy of General Dentistry, the International Congress of Oral Implantologists, the Pierre Fauchard Academy, American College of Dentists, Masterships in The Academy of General Dentistry and the Implant Prosthetic Section of the International Congress of Oral Implantologists. Additionally, a former Assistant Program Director for a University based implant maxi-course. He can be reached at dr_kurtzman@marylandimplants.com

AD

www.apdc2007jakarta.com

Trend, Technology, and Innovation in Comprehensive Oral Health Care

29th Asia Pacific Dental Congress
April, 25th - 29th 2007, Jakarta Convention Centre

PROGRAM:

- APDF Meeting
- Lectures & Symposium
- Course & Table Clinic
- Military Dentist Symposium
- Congress Workshop
- APEC Symposium
- Dental Trade Exhibition

Organized by:

Asia Pacific Dental Federation (APDF) and Indonesian Dental Association (PDI)

Congress Secretariat
Hang Lekir Raya 26
Jakarta 12120, Indonesia
e-mail: pbdgi@cbn.net.id
tel: +62 21 726 0088
fax: +62 21 739 7555